


PATIENT

Nigel Milford-Clare

PRESENTING CLINICAL SIGNS

 History: Recheck echo. Grade 5/6 heart murmur.
 -Pertinent previous echo findings (3/2022 MML): Trivial MR, no LVH, mild AS, trace AI. AV
 max: 2.2, LA: 2.5, LV: 4.4.

SPECIES

Canine

ELECTROCARDIOGRAPHIC FINDINGS *Note: Single lead ECGs are evaluated as a rhythm strip. Morphology/MEA cannot be definitively commented on.

A single lead ECG is available; 50mm/s, 20mm/mV. The average heart rate is 110bpm (range 81-130bpm). The rhythm is sinus in origin, with a p for every QRS complex and vice versa. The P and QRS morphologies are positive. No ectopic beats, pauses or other dysrhythmias observed.

BREED

French Bulldog

ECG diagnosis: Normal sinus rhythm with respiratory variation.

SEX

Male Neutered

ECHOCARDIOGRAM FINDINGS

2D, m-mode, color flow and doppler imaging is available. Normal mitral valve leaflets with no prolapse into the left atrial lumen. Trivial mitral regurgitation with normal left atrial dimension. Normal LV diameter with adequate myocardial function. Normal LV wall dimensions with no obvious hypertrophy. The tricuspid valve appears normal with trace tricuspid regurgitation. Normal right atrial and ventricular diameter and morphology indicating no overt evidence of pulmonary arterial hypertension. The pulmonic valve appears normal in morphology and mobility. Normal pulmonic outflow velocities with laminar flow. Mild thickening of the aortic valve. The LVOTO velocity is normal, suspected to be an underestimation. Mild aortic insufficiency. No pericardial or pleural effusion noted. No obvious cardiac masses.

AGE

6 years

WEIGHT

39.5lbs

INTERPRETED BY

 Maggie Machen Lamy,
 DVM DACVIM
 (Cardiology)

CARDIAC CHART
IMAGING PERFORMED BY

Kelly Reschny, RVT

HOSPITAL NAME

 Beattie Pet Hospital
 Burlington

REFERRING VET

Dr. Murota

INVOICE

29392

DATE

3/6/23

CANINE CARDIAC PARAMETERS	MR VMAX (m/s)	TR VMAX (m/s)	LA/AO (Boon method)	LA/AO (Heart Base; Swe)	FS (%)	EF (%)	EPSS (cm)
NORMAL PARAMETER	4.5-5.5	<2.7	1.3	<1.6	28-40	40-100	<0.6
PATIENT	NM	NM	1.1	1.2	28	54	0.6
CANINE CARDIAC PARAMETERS	HR (BPM)	AV VMAX (m/s)	PV MAX (m/s)	BODY WEIGHT (kg)	LA 2D short axis Base view (cm)	LVIDd Avg; 2D and m-mode short axis (cm)	LVIDs Avg; 2D and m-mode short axis (cm)
NORMAL PARAMETER	50-100	0.7-1.7	0.7-1.6	BELOW	BELOW	BELOW	BELOW
PATIENT	100	1.5	1.3	17.9	2.3	3.9	2.9
*Normal chamber parameters expressed as a mean value (SD)				3	1.27 (5.3)	2.46 (2.46)	1.36 (5.5)
BODY WEIGHT DEPENDENT PARAMETERS				5	1.40 (4.5)	2.74 (5.2)	1.60 (4.7)
<i>*Note: All measurements based upon multi-modal images and methods. An average value is reported.</i>				10	1.50 (3.8)	3.27 (3.5)	2.06 (3.1)
				15	1.83 (2.0)	3.71 (2.4)	2.43 (2.1)
				20	2.02 (1.9)	4.14 (2.2)	2.80 (2.0)
				25	2.18 (2.4)	4.48 (2.9)	3.10 (2.5)
				30	2.33 (3.3)	4.83 (3.9)	3.39 (3.4)
				35	2.48 (4.3)	5.17 (5.0)	3.69 (4.5)
				40	2.62 (5.2)	5.48 (6.1)	3.96 (5.4)
				50	2.88 (7.1)	6.07 (8.3)	4.46 (7.4)

 Adapted from June Boon, Veterinary Echocardiography, 1998
 Rishniw M and Hollis NE, J Vet Intern Med 2000; 14:429-435
 Hansson et al, Vet Rad and Ultrasound 2002
 Bonagura et al. Echocardiography: principles of interpretation, Vet Clin North Am 15:1177, 1995



PATIENT

Nigel Milford-Clare

SPECIES

Canine

BREED

French Bulldog

SEX

Male Neutered

AGE

6 years

WEIGHT

39.5lbs

INTERPRETED BY

Maggie Machen Lamy,
DVM DACVIM
(Cardiology)

IMAGING PERFORMED BY

Kelly Reschny, RVT

HOSPITAL NAME

Beattie Pet Hospital
Burlington

REFERRING VET

Dr. Murota

INVOICE

29392

DATE

3/6/23

INTERPRETATION OF THE FINDINGS & FURTHER RECOMMENDATIONS

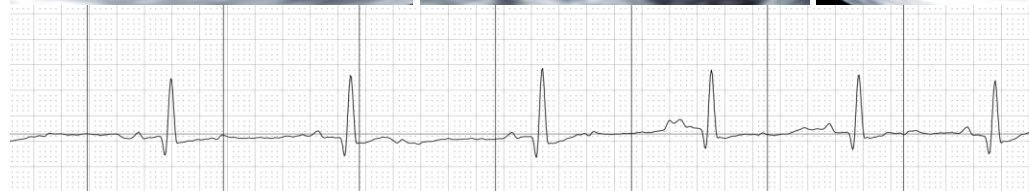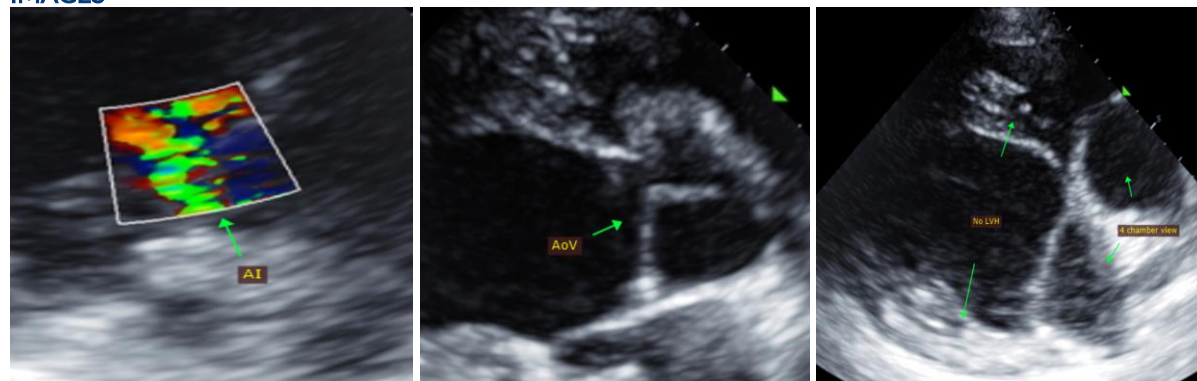
Compared to the prior study, findings are similar. The aortic outflow velocity is suspected to be an underestimation with mild stenosis persisting. The aortic leak is slightly increased comparatively and a baseline BP is recommended. No additional issues are identified. The ECG is unremarkable with a respiratory sinus arrhythmia.

No cardiac medications remain indicated at this time. From a cardiac standpoint, monitor for development of collapse episodes, labored breathing or exercise intolerance, as AS patients are more predisposed to development of arrhythmias than to CHF (particularly Boxers and Bulldogs).

Anesthetic risk is low. Avoid heart rate stimulating drugs such as atropine or glycopyrrolate unless clinically indicated. Recommend prophylactic antibiotics for any orthopedic or dental procedure in the future given slight predisposition to endocarditis.

Recommend recheck echocardiogram every 1-2 years to ensure no progression is seen, and to screen for development of concurrent cardiac disease that the preexisting murmur may mask.

IMAGES



The information and recommendations provided are based on the images presented by the referring veterinarian. No evaluation can be communicated regarding pathology that was not visible in the image/video clips provided.

Thank you for this referral. This report was generated using transcription software, and minor dictation errors may be present. If the clinical or image interpretation does not parallel your findings or if I can be of any further assistance, please contact me.

Maggie Machen Lamy, DVM
Diplomate of the American College of Veterinary Internal Medicine (Cardiology)
info@sonopath.com